

MICRO LARYNGEAL SURGERY: 25 CASES OF BENIGN LESIONS OF LARYNXShanta Nibedita Satpathy¹, Swatishree Dash²**HOW TO CITE THIS ARTICLE:**

Shanta Nibedita Satpathy, Swatishree Dash. "Micro Laryngeal Surgery: 25 Cases of Benign Lesions of Larynx". Journal of Evolution of Medical and Dental Sciences 2014; Vol. 3, Issue 57, October 30; Page: 12907-12912, DOI: 10.14260/jemds/2014/3713

ABSTRACT: Micro Laryngeal Surgery (MLS) is a procedure where the larynx is seen with the help of endoscope and the view is magnified by use of an operating microscope. This has numerous advantages in regard to delineating the extent of lesion and performing a satisfactory excision or biopsy. This is the procedure of choice in assessment as well as treatment of benign lesions of larynx. Patients who are voice users were benefited by the procedure by getting back their normal voice. Study group comprise of 25 patients with age group varying from 12-48 years. Various abnormalities were detected among these patients, vocal nodule being the commonest. Other pathologies were vocal cord polyp, Reinke's Oedema, ventricular cyst, chronic laryngitis, tuberculosis and papillomatosis of larynx. MLS is safe, effective and smoothly performed procedure giving a person back his normal voice.

KEYWORDS: Micro laryngeal Surgery, benign lesions of larynx.

INTRODUCTION: The development endolaryngeal microsurgery began with the histological investigations of precancerous lesions. Karl Storz in 1958-1959 built a laryngoscope with a movable 10 fold prismatic optical magnifying system attached to the handle and named it laryngeal microscope. This instrument was originally designed for diagnostic purposes. Patient was taken under local anaesthesia. Klein Sasser, an otolaryngologist and pathologist in 1958 added magnifying telescope to the Hollinger anterior commissure laryngoscope, later he combined it with chest support. Thus endo-laryngeal microsurgery started. Later Zeiss microscope with 400mm objective was obtained. Finally K Hopman and Renier introduced a new set of instruments for MLS.

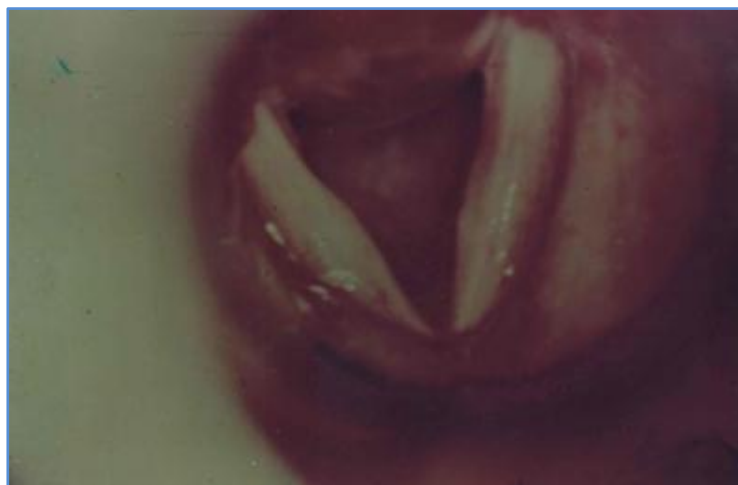

Fig. 1: Normal Larynx

ORIGINAL ARTICLE

METHOD: This study was conducted in INHS ASHWINI Colaba, Bombay from July 1995 to December 1996. All patients with complains of hoarseness, chronic cough, foreign body sensation in throat, dysphagia, dyspnoea, haemoptysis, dysphonia were included in the study. In most of the patients some contributory factor was present such as over use of voice, cigarette smoking, unfavourable working condition or history of previous intubation. The procedure was done after taking written informed consent. All the patients were subjected to indirect laryngoscopy before MLS. Patients with cervical spondylosis and patients unfit for general anaesthesia were not included in the study.

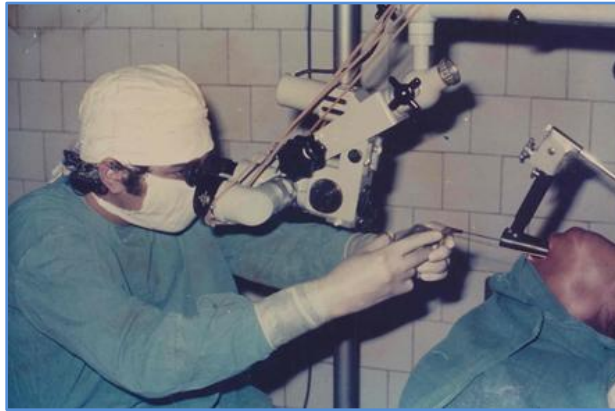

Fig. 2: MLS in OT, INHS Ashvini

RESULTS: The present study is an analysis of 25 patients with benign laryngeal lesion commonest being vocal cord polyp in 32%, while vocal nodule in 24%, Rienkes oedema in 20%. Tuberculosis of Vocal Cord and juvenile papillomatosis were very rare. Most benign VC lesion were in the age group of 21 to 30 years (Table-1) while juvenile papilloma is seen in small children (Table-2). There is a female predominance M: F ratio being 2:3. (Table-3). The main presenting symptom was hoarseness (52%) as shown in table 4. All the cases were examined thoroughly, investigated completely and they were taken up for MLS. Tissue was sent for HPE and diagnosis was confirmed. Most of the patients improved with surgery and there was no complication.

Serial No.	Lesions	No. of Cases	%
1	Vocal Cord Polyp	8	32
2	Vocal Cord Nodules	6	24
3	Reinke's Oedema	5	20
4	Ventricular Cyst	2	8
5	Chronic Laryngitis	2	8
6	Tuberculosis	1	4
7	Papillomatosis	1	4
Total		25	100

Table 1: Percentage of benign lesions of Larynx

ORIGINAL ARTICLE

Serial No.	Lesions	0-10 Years	11-20 Years	21-30 Years	31-40 Years	> 40 Years
1	Vocal Cord Polyp	-	01	05	02	-
2	Vocal Cord Nodules	-	01	03	02	-
3	Reinke's Oedema	-	-	01	01	03
4	Ventricular Cyst	-	-	-	02	-
5	Chronic Laryngitis	-	-	01	01	-
6	Tuberculosis	-	-	01	-	-
7	Papillomatosis	01	-	-	-	-

Table 2: Lesions in relation to age incidence

Serial No.	Lesions	Male	Female	Total
1	Vocal Cord Polyp	03	05	08
2	Vocal Cord Nodules	02	04	06
3	Reinke's Oedema	01	04	05
4	Ventricular Cyst	01	01	02
5	Chronic Laryngitis	02	-	02
6	Tuberculosis	-	01	01
7	Papillomatosis	01	-	01

Table 3: Lesions in relation to sex

Serial No.	Lesions	No. of Cases	%
1	Hoarseness	8	32
2	Chr. Cough	6	24
3	Foreign body sensation	5	20
4	Dysphagia	2	8
5	Dysphonia	2	8
6	Haemoptysis	1	4
7	Dyspnoea	1	4

Table 4: Pre-op percentage of various symptoms

DISCUSSION: The most common benign lesion of larynx presenting with hoarseness is vocal cord polyp. They arise from the membranous part of Vocal Cord. They are not tumours. On Histopathological examination the polyp shows typical appearance of oedema of sub-epithelial tissue with combination of basophil and hyaline degeneration and fibrosis. Post-surgery patients had very good voice. Vocal Nodules are translucent, soft mucosal protuberances, usually bilateral. It affects people who misuse or overuse their voice. HPE demonstrates slightly thickened squamous epithelium with sub-mucosal infiltration of loose inflammatory cells. Larger nodules demonstrate relatively dense fibrosis immediately under basal membrane. 50% patients had dramatic

ORIGINAL ARTICLE

improvement of voice. Klein Sasser's study states that 80% patients regain normal voice, 5% had recurrence and 15% need speech therapy for residual hoarseness.

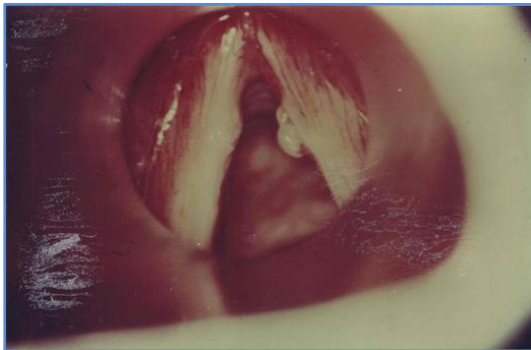


Fig. 3: Vocal Cord Polyp

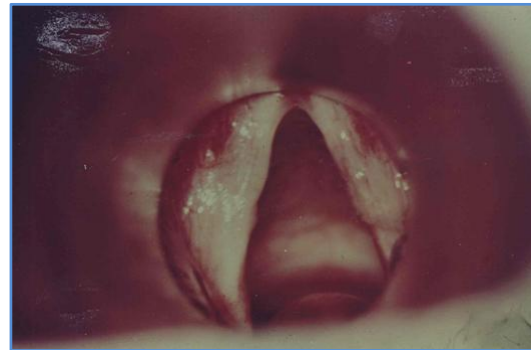


Fig. 4: Vocal Cord After Removal of Polyp

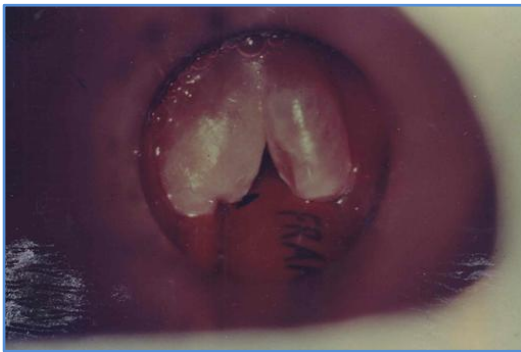


Fig. 5: Rienke's Oedema

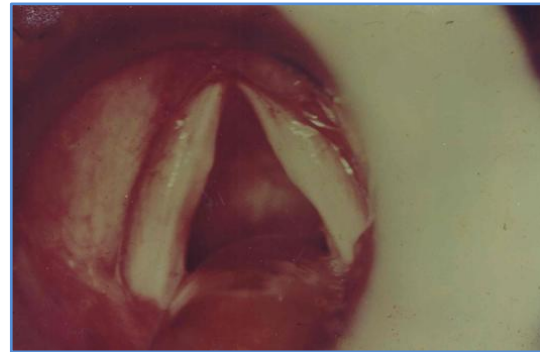


Fig. 6: Vocal Cord After Surgery for Rienke's

Rienkes oedema or polypoid corditis was named after F. Rienkes (1895), an anatomist. There HPE shows gelatinous fluid in a fine honeycomb network beneath the squamous epithelium of Vocal Cord. Oedema is drained by stripping of vocal cord and sucking out the fluid by MLS and voice improves. Ventricular cysts, usually solitary and unilateral, are lined by squamous or columnar epithelium containing watery thin or mucoid material.

HPE of chronic hyperplastic laryngitis shows thick squamous epithelium with pronounced acanthosis without nuclear atypia. Sub-mucosal zone shows inflammatory infiltrates. In TB larynx there is cookie bite ulcer in the posterior 1/3rd of Vocal Cord. Biopsy done by MLS helps in diagnosis of Tuberculosis. Juvenile papillomatosis which affects children begins on the Vocal Cord and extends to supra glottis or sub glottis. We had one case of Juvenile papillomatosis presenting with dyspnoea and hoarseness. MLS was done and papilloma was exercised. On follow up after 6 months no recurrence was seen.

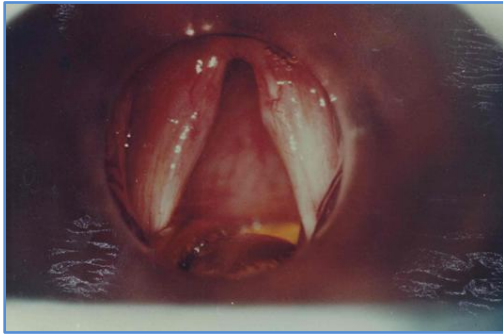


Fig. 7: Chronic Hyperplastic Laryngitis

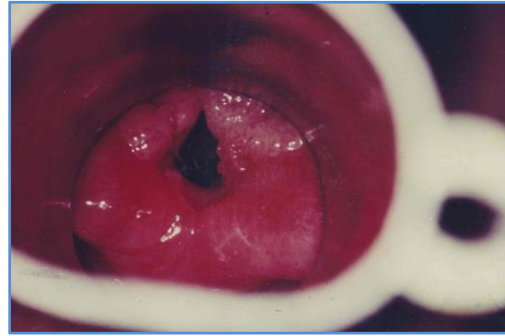


Fig. 8: Juvenile Papillomatosis

CONCLUSION: There are more than one reason for hoarseness of voice. A thorough pre-operative examination and evaluation for G.A. is required for MLS. Major patients are voice users. MLS improves the quality of voice and quality of life as well. For a singer or a teacher it becomes absolutely necessary to have a good voice which can be achieved by MLS.

BIBLIOGRAPHY:

1. History of otorhinolaryngology, Scott Stvenson and Douglas Gauthric, published by S. Livingstone Ltd – 1949.
2. Microlaryngoscopy and Endolaryngeal Microsugery by O. Kleinsasser, 3rd ed;1995.
3. Scott Brown's Otolaryngology, vol.1;5th ed.1987.
4. Logan Turner's Diseases of the nose, Throat and ear, 10th ed.1988.
5. Wilson's Diseases of Ear, Nose and Throat, London, 1962.
6. Improved Laryngoscope for use with operative microscope by D.R. Bus, Archives of Otolaryngology 91: 195, 1970
7. Microsurgery of larynx, Kurzeler D., Archives of otolaryngology, 93: 521, 1971.
8. Paperella and Shimrick, otolaryngology Vol. 3, 1980, 2nd ed.
9. Laryngoscope for Microscopic Observation, Surgery and Photography, Archives of Otolaryngology, 94:151, 1971.
10. Microlaryngeal Surgery, Lempert J.A., Archieves of otolaryngology, 94: 151, 1971.
11. Vocal Cord Nodules and polyps, Role of surgical treatment, strong S.M. and Vaughan C.W. laryngoscope, LXXXI, 911, 1971.
12. Suspension Apparatus for Laryngeal Microsurgery, Thomas Gill, Archives of Otolaryngology, 94: 258, 1971.
13. Surgical Microscopy of larynx, Thomson J.R., Green C.H., Cale W., Laryngoscope LXXXI, 772.
14. A New Adult Microlaryngoscope by Bruce Benzamine FRACS, Annals of Otorhinolaryngology, 95, 1986.
15. Bronchoesophagology by Chevalier Jackson, 1964.

ORIGINAL ARTICLE

AUTHORS:

1. Shanta Nibedita Satpathy
2. Swatishree Dash

PARTICULARS OF CONTRIBUTORS:

1. Associate Professor, Department of ENT, Hi-Tech Medical College, Bhubaneswar, Orissa.
2. Consultant ENT Surgeon, Department of ENT, Kochi, Kerala.

NAME ADDRESS EMAIL ID OF THE CORRESPONDING AUTHOR:

Dr. Shanta Nibedita Satpathy,
47, Jaydev Nagar,
Nageswar Tangi Housing Board Colony,
Bhubaneswar-751002,
Odisha.
Email: shantasatpathy@gmail.com

Date of Submission: 11/10/2014.
Date of Peer Review: 13/10/2014.
Date of Acceptance: 18/10/2014.
Date of Publishing: 28/10/2014.